

## Case Report

# Intrathoracic Fluid Extravasation After Hip Arthroscopy

Maneesh Verma, M.D., and Jon K. Sekiya, M.D.

---

**Abstract:** The case of intrathoracic extravasation of irrigation fluid after hip arthroscopy in a 21-year-old woman is presented. In this patient intraperitoneal and retroperitoneal fluid collection developed, as seen in other case reports documenting irrigation fluid extravasation during hip arthroscopy. The patient presented to the emergency department on the first postoperative day complaining of shortness of breath. Computed tomography of the chest, abdomen, and pelvis showed retroperitoneal fluid, extensive abdominal ascites, and bilateral pleural effusions within the chest. The fluid diminished pulmonary volume by elevating the diaphragm and causing compression atelectasis of both lungs. The patient's hemodynamic status was stable and unaffected. She developed hypothermia during the procedure, which is consistent with other reports on extravasated irrigation fluid during arthroscopy. She was able to rapidly compensate for fluid overload and eliminated it uneventfully, with resolution of her symptoms. A similar procedure was performed on the contralateral hip 6 months later. During that procedure, there was a suspected (not confirmed) recurrence of intraperitoneal extravasation of the pump fluid as well as transient hypothermia, which resolved by the first postoperative visit. The physiologic effects of intrathoracic fluid accumulation and the literature regarding extravasation of irrigation fluid during hip arthroscopy are also reviewed.

---

The orthopaedic surgeon's use of the arthroscope to treat intra- and extra-articular hip pathology is expanding. Overall, complications occur less than 2% of the time. The most common complications associated with hip arthroscopy are neurapraxia, portal wound hematoma, portal wound bleeding, trochanteric bursitis, and instrument breakage.<sup>1</sup> A rare complication with potentially devastating outcomes is extravasation of the irrigation fluid into the intraperitoneal and retroperitoneal spaces. This fluid can rapidly accumulate within the abdominal cavity and lead to disastrous

consequences such as abdominal compartment syndrome and cardiac arrest.<sup>2-4</sup>

We present a case in which the irrigation fluid extravasated into the thoracic cavity, in addition to accumulating within the intraperitoneal and retroperitoneal cavities. The extent of extravasation documented in our patient exceeds that of previous reports. The warning signs and risk factors for fluid extravasation during hip arthroscopy will be discussed. In addition, the pathophysiology of the complications associated with excess fluid extravasation into the thoracic cavity will be reviewed.

---

*From the Department of Orthopaedic Surgery, University of Michigan Health System (M.V.), and MedSport (J.K.S.), University of Michigan, Ann Arbor, Michigan, U.S.A.*

*J.K.S. has received support exceeding US \$500 related to this research from OrthoDynamix, Jacksonville, Florida.*

*Address correspondence and reprint requests to Jon K. Sekiya, M.D., MedSport-Department of Orthopaedic Surgery, University of Michigan, 24 Frank Lloyd Wright Dr, PO Box 0391, Ann Arbor, MI 48106-0391, U.S.A. E-mail: [sekiya@umich.edu](mailto:sekiya@umich.edu)*

*© 2010 by the Arthroscopy Association of North America  
0749-8063/1017/\$36.00*

*doi:10.1016/j.arthro.2010.02.019*

## CASE REPORT

A 21-year-old woman with 18 months of right-sided hip pain elected to undergo hip arthroscopy for treatment of cam-type femoroacetabular impingement, snapping iliopsoas tendon, and capsular laxity. Conservative treatment of her hip disease had failed. Arthroscopy was carried out with the patient in the supine position with the right hip distracted with a

lower limb traction device for the intra-articular portion of the case. We first created the anterolateral portal under fluoroscopic guidance. A 70° arthroscope was inserted through this portal and used to help establish the anterior portal under direct visualization. Normal saline solution with epinephrine was used for the irrigation fluid. The pump pressure was set at 100 mm Hg for the entire case, and all cannulas were left open to allow for constant outflow of the irrigation fluid. The diagnostic portion of the arthroscopy showed cam-type impingement, with no evidence of labral tear. A small capsulotomy was created anteriorly, and the musculotendinous portion of the iliopsoas tendon was identified. This was lengthened by 1.5 cm with a Beaver blade. At this point, the peripheral compartment was established. An osteoplasty was performed to treat the femoroacetabular impingement. The anterior capsule was then plicated and the portals closed.

During the procedure, which lasted 139 minutes, the patient's temperature had decreased from 36.6°C to 34.2°C. She was otherwise hemodynamically stable. At the completion of extubation and removal of the operative drapes, her right thigh circumference was significantly enlarged compared with the contralateral side. She had a distended and firm abdomen, but it was still easily compressible. Bowel sounds were present and normal. Her right labia was asymmetrically enlarged. In the post-anesthesia care unit, the patient was able to void independently and did not complain of abdominal discomfort. Her bowel sounds continued to be present, and she was discharged home after a discussion with her father and with the anesthesia staff.

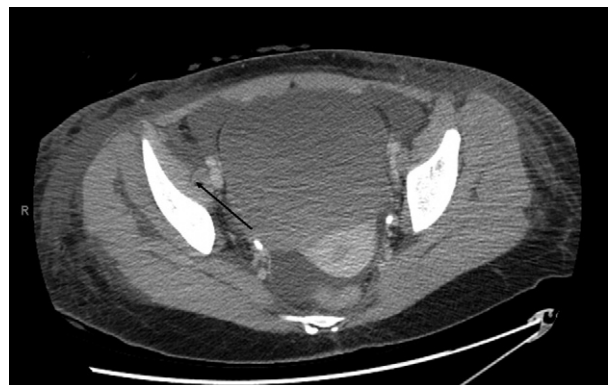
The next day, the patient called our office complaining of shortness of breath, so we immediately referred her to our hospital's emergency department. She underwent computed tomography (CT) scan of the chest, abdomen, and pelvis to rule out pulmonary embolism. She was found to have bilateral pleural effusions, bilateral compression atelectasis, extensive abdominal ascites, retroperitoneal soft-tissue edema (specifically within the psoas muscle), and widespread subcutaneous edema. She denied any history of abdominal pain and was eating a regular diet while in the emergency department. Further evaluation showed a normal complete blood count, D-dimer assay, and electrocardiogram. Her vital signs were always within normal limits. At the time we evaluated her in the emergency department, approximately 24 hours had passed since the operation. She began to have frequent urination and resolution of her shortness of breath. We discussed the case with the admitting internist and con-

cluded that the acute accumulation of fluid seen on CT was extravasated irrigation fluid from her surgical procedure. In addition, the patient had shown the ability to compensate for this fluid overload and was actively eliminating it from her body. She was discharged home. At her follow-up appointment 8 days later, she no longer showed any characteristics of fluid overload. At 3 months' follow-up, she reported 95% improvement in her preoperative symptoms and scheduled surgery for her contralateral hip with similar but less severe symptoms.

The patient elected to undergo a similar procedure on the contralateral hip 6 months later. This time, the pump pressure was set to 70 mm Hg in an effort to avoid the previous complication. Throughout the case, we noticed difficulty maintaining the preset pump pressure. At the conclusion of the case, the patient once again had symptoms consistent with fluid extravasation. Her thigh circumference was enlarged, and she had a distended but compressible abdomen. In addition, her core temperature had fallen to 35.7°C. She recovered uneventfully from this episode of fluid extravasation with self-diuresis.

## DISCUSSION

Fluid extravasation is a rare complication of hip arthroscopy, with only 5 reported cases in the English-language literature (Table 1). However, the manifestations of such an event can be disastrous. The first case was reported in 1998, when hip arthroscopy was performed to retrieve a loose body 12 days after open reduction-internal fixation of an acetabular fracture.<sup>2</sup> In this case the irrigation fluid extravasated directly



**FIGURE 1.** CT scan of pelvis with patient supine. The arrow points to the extravasated fluid within the iliopsoas musculature. Once the tendon sheath to the iliopsoas is incised, irrigation fluid is able to track along the tendon and into the retroperitoneum.

**TABLE 1.** *Cases of Fluid Extravasation After Hip Arthroscopy*

Author	Year	Indication	Outcome	Treatment
Bartlett et al. <sup>2</sup>	1998	Retrieval of loose bodies after acetabular fracture fixation	Death	
Haupt et al. <sup>5</sup>	2008	Intra-articular adhesions	Intra-abdominal accumulation	Observation
Sharma et al. <sup>3</sup>	2009	Labral tear	Abdominal compartment syndrome	Emergency laparotomy
Fowler and Owens <sup>4</sup>	2010	Femoral acetabular impingement	Abdominal compartment syndrome	Emergency laparotomy
Ladner et al. <sup>6</sup>	2010	Femoral acetabular impingement	Intra-abdominal accumulation	Intravenous furosemide/observation
Current study	2010	Femoral acetabular impingement	Intra-thoracic and abdominal accumulation	Observation

into the abdominal cavity through the fractured acetabulum. Cardiac arrest developed in the patient, and the authors concluded that hip arthroscopy was contraindicated in the setting of acute or healing acetabular fractures.

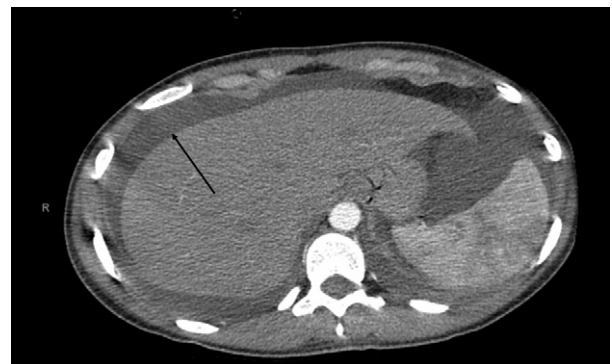
Haupt et al.<sup>5</sup> reported the case of a 15-year-old girl who complained of abdominal pain after hip arthroscopy. Ultrasound of the abdomen showed 3 L of retroperitoneal and intraperitoneal fluid. Repeat ultrasound 16 hours later showed complete resorption of this fluid. The authors noted that the patient had an acute temperature drop during the procedure and suggested that a sudden decrease in core body temperature should raise suspicion for intra-abdominal fluid accumulation. Unfortunately, many patients undergoing arthroscopic surgery may exhibit some degree of hypothermia, so this may be a less specific warning sign.

Ladner et al.<sup>6</sup> recently reported the case of a 42-year-old woman who was treated nonoperatively for abdominal fluid extravasation after hip arthroscopy for femoroacetabular impingement. Two intravenous doses of furosemide were administered immediately after it was recognized that a largely distended abdomen had developed in the patient, consistent with fluid extravasation. She produced over 3 L of urine and recovered uneventfully. A CT scan showed intraperitoneal and retroperitoneal fluid.

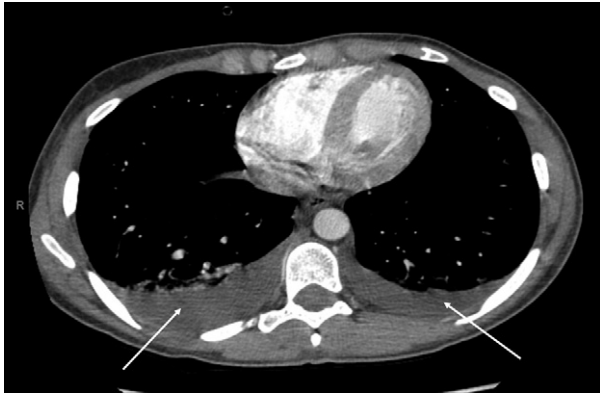Emergency laparotomy for the treatment of acute abdominal compartment syndrome due to fluid extravasation after hip arthroscopy has been reported twice. The first case occurred in a 45-year-old woman who underwent arthroscopy for treatment of a labral tear and psoas release.<sup>3</sup> At the completion of the procedure, the patient's core temperature dropped to 33.3°C and she had acute hypotension. Her abdomen was grossly distended, and emergency laparotomy was

performed to treat her abdominal compartment syndrome. Three liters of colorless irrigation fluid was drained from the abdomen, and the hemodynamic status immediately normalized. The second case involved a 42-year-old man whose abdomen became extremely distended during hip arthroscopy.<sup>4</sup> An emergency decompressive laparotomy was performed for abdominal compartment syndrome, which yielded over 1 L of serosanguineous fluid. The retroperitoneum was boggy with a track of fluid along the iliopsoas muscle. This patient required staged primary closure of the abdomen.

In these nontraumatic cases, the irrigation fluid traveled into the abdominal cavity through a retroperitoneal approach. We propose a similar mechanism of extravasation for our patient. Once the tendon sheath of the iliopsoas muscle is opened, the irrigation fluid is free to travel into the retroperitoneum. Fluid can clearly be seen



**FIGURE 2.** CT scan of abdomen with patient supine. A large amount of abdominal ascites surrounding the liver (arrow) can be visualized. This represents extravasated irrigation fluid within the peritoneal cavity.



**FIGURE 3.** CT scan of chest with patient supine. Large, bilateral pleural effusions (arrows) developed because of extravasation of irrigation fluid into the thorax. The fluid is thought to have tracked along the retroperitoneal space into the peritoneum and finally into the thorax.

within the psoas muscle on the CT scan (Figs 1-3). We hypothesize that this patient has a communication between her retroperitoneal and peritoneal cavity that allowed for this amount of fluid extravasation. Essentially, her peritoneal cavity is not a closed compartment. Therefore, even with a low pump pressure, there was constant extravasation of pump fluid and difficulty maintaining our preset pump pressure.

Unlike the previously reported cases, the irrigation fluid extravasated beyond the abdomen and into the thoracic cavity. Accumulation of fluid within the thorax exacerbates the physiologic effects of abdominal hypertension and abdominal compartment syndrome. Thoracic fluid impairs pulmonary function through extrinsic compression of the lungs, reduced chest wall compliance, and atelectasis. Cardiac function also can become impaired as the accumulating fluid reduces ventricular compliance. As compliance reduces, the contractile force of the ventricle diminishes, as evidenced by the Starling curve. In addition, with extrinsic pulmonary compression, afterload within the pulmonary circuit increases. These physiologic effects on the cardiopulmonary system are also seen in abdominal compartment syndrome, and the topic of abdominal compartment syndrome has recently been reviewed by Sharma et al.<sup>3</sup> In the event of fluid extravasation during hip arthroscopy with acute cardiopulmonary failure, thoracic fluid may be present but it would be due to a large intra-abdominal fluid collection. Emergency treatment of the intra-abdominal fluid should be the immediate focus to restore end organ function. We

**TABLE 2.** Warning Signs of Arthroscopic Fluid Extravasation

Inability to distend joint
Increasing fluid requirements to maintain joint distention
Frequent cutoff of pump irrigation system
Abdominal and thigh distention
Acute hypothermia

propose that extrinsic compression from the thoracic fluid, as well as the elevated diaphragm from the intra-abdominal fluid, caused our patient to be short of breath.

## CONCLUSIONS

It is important to understand that the healthy patient can rapidly absorb and eliminate extravasated irrigation fluid. This is because of the large surface area provided by the peritoneal lining of the abdomen.<sup>7</sup> As long as there is no evidence of hemodynamic compromise, observation is sufficient. However, the orthopaedic surgeon must recognize the disastrous potential of extravasated pump fluid. Abdominal compartment syndrome, hypotension, and cardiac arrest have all been observed and require aggressive treatment. Rapid accumulation of peritoneal fluid can cause venous compression within the abdomen. Patients with fluid overload disorders (congestive heart failure, end-stage renal disease, liver failure, and so on) may be poor candidates for hip arthroscopy because their ability to compensate for extravasated pump fluid is compromised. Lastly, it is important to remember the 5 warning signs of extravasation: (1) inability to distend the joint, (2) increased fluid requirement to maintain distention, (3) frequent cutoff of pump irrigation systems, (4) abdominal and thigh distension, and (5) acute hypothermia (Table 2). We present this case to raise awareness of this potential complication that can occur from standard hip arthroscopy.

## REFERENCES

1. Clarke MT, Arora A, Villar RN. Hip arthroscopy: Complications in 1054 cases. *Clin Orthop Relat Res* 2003;(406):84-88.
2. Bartlett CS, DiFelice GS, Buly RL, Quinn TJ, Green DS, Helfet DL. Cardiac arrest as a result of intraabdominal extravasation of fluid during arthroscopic removal of a loose body from the hip joint of a patient with an acetabular fracture. *J Orthop Trauma* 1998;12:294-299.
3. Sharma A, Sachdev H, Gomillion M. Abdominal compartment syndrome during hip arthroscopy. *Anaesthesia* 2009;64:567-569.

4. Fowler J, Owens BD. Abdominal compartment syndrome after hip arthroscopy. *Arthroscopy* 2010;26:128-130.
5. Haupt U, Völkle D, Waldherr C, Beck M. Intra- and retroperitoneal irrigation liquid after arthroscopy of the hip joint. *Arthroscopy* 2008;24:966-968.
6. Ladner B, Nester K, Cascio B. Abdominal fluid extravasation during hip arthroscopy. *Arthroscopy* 2010;26:131-135.
7. Moore KL, Dalley AF. *Clinically Oriented Anatomy*. Ed 4. Baltimore: Lippincott Williams & Wilkins, 1999.